

**CASE REPORT**

# Successful treatment of distichiasis in a cow using a direct-contact 810-nm diode laser

Kevin Arteaga DVM, MSc  | Manuela Crasta DVM, PhD, Dipl ECVO

Visionvet, Eye Clinic, San Giovanni in Persiceto, Bologna, Italy

**Correspondence**Kevin Arteaga, Visionvet, Eye Clinic, Via Enrico Fermi 65, San Giovanni in Persiceto, 40017, Bologna, Italy.  
Email: kevinof91@hotmail.com**Abstract****Objectives:** To describe the use of direct-contact diode laser as a new treatment for distichiasis.**Study design:** Case report.**Animals:** A 2-month-old Italian Friesian calf with bilateral excessive tearing and corneal opacification was presented to the Visionvet Eye Clinic. Abnormalities on ophthalmic examination included epiphora, seromucous discharge, bilateral distichiasis and secondary chronic keratitis affecting both eyes.**Methods:** Distichiae were surgically removed after insertion of the 810-nm diode laser tip into the associated meibomian gland.**Results:** Clinical signs gradually improved postoperatively with minimal and transient post-operative complications. Ophthalmic examination was within normal limits 6 months later beyond distichiae.**Conclusion:** Treatment of distichiasis with direct-contact 810-nm diode laser resulted in long-term resolution of signs in the case described here.

## 1 | INTRODUCTION

Distichiae are abnormal hairs emerging from Meibomian gland orifices onto the free lid margin, or less frequently from the Zeis or Moll openings.<sup>1,2</sup> Distichiasis is a frequent disorder in dogs and has also been reported in a cat, a horse a ferret and a bull.<sup>1,2-6</sup> Even though the precise mode of inheritance is not clearly defined, distichiasis is assumed to be an inherited condition in some canine breeds, such as English Cocker Spaniel, English Bulldog, Pekingese, Welsh Springer Spaniel, Boxer, Cavalier King Charles Spaniel, among others.<sup>1</sup> Clinical signs, when present, are due to chronic rubbing of the cilium against the cornea.<sup>7</sup>

Different treatments have been considered with variable rates of success. Unlike simple manual epilation, permanent corrective surgery aims to redirect hair away from the ocular surface or destroy the hair follicle, thus decreasing the risk of possible

regrowth.<sup>1,2</sup> Surgical treatment options reported in veterinary medicine include: electrolysis, electrocautery, cryotherapy, conjunctival resection, splitting eyelid with tarsoconjunctival resection, CO<sub>2</sub> laser, partial tarsal plate excision, and Celsus–Hotz technique.<sup>8-13</sup> In addition to recurrence, scarring, eyelid distortion, cicatricial entropion, eyelid depigmentation, and qualitative tear film deficiency had been described as postoperative complications of these surgical distichiasis techniques.<sup>1,8-13</sup>

In 1979, laser photocoagulation therapy for trichiasis was first proposed by Berry.<sup>14</sup> A human study later confirmed that direct-contact diode laser is an efficient tool to treat trichiasis.<sup>15</sup> No postoperative complications were reported after the surgical procedure.<sup>15</sup> To the best of our knowledge, there is no published article in veterinary ophthalmology regarding the use of diode laser technology for treating eyelash disorders.

This case report describes the clinical presentation of bilateral distichiasis in a cow and resolution of clinical

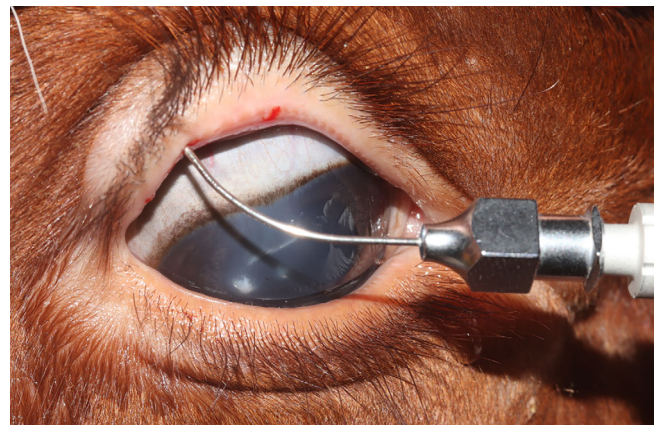
signs following photocoagulation therapy with a direct-contact 810-nm diode laser.

## 2 | MATERIALS AND METHODS

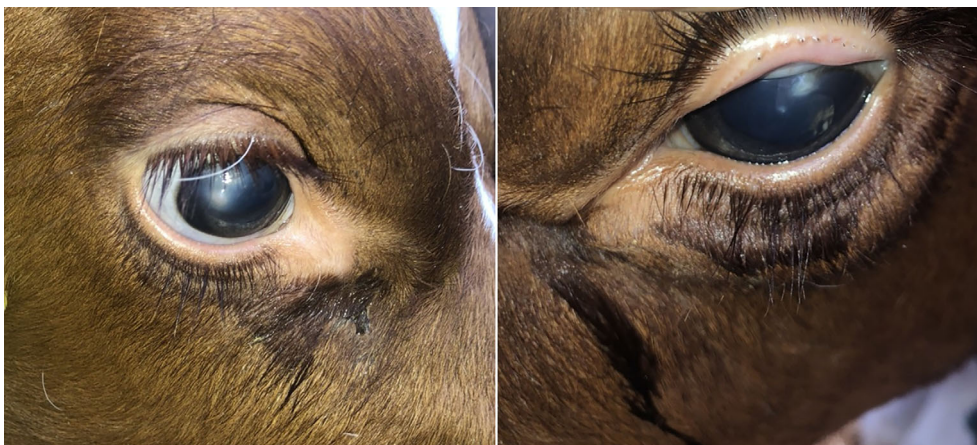A 2-month-old female intact Italian Friesian calf was presented to Visionvet Eye Clinic for evaluation of bilateral squinting and corneal opacities. The owner reported that ocular signs were present since 1 month of age. The calf had been treated with topical tobramycin twice daily for 2 weeks without improvement. On presentation, the animal was conscious and alert, and no general physical abnormalities were noted. A gentle manual restraint was sufficient to perform the ocular examination. Ophthalmological examination revealed normal menace response, dazzle reflex, palpebral, and pupillary light reflexes. Bilateral mild seromucous discharge accompanied with abundant bilateral epiphora was present (Figure 1). Schirmer tear test I (Schirmer Tear Test, MSD Animal Health) was greater than 35 mm in 1 min in both eyes (OU). Hand-held slit lamp biomicroscopy (SL-17, Kowa Company Ltd) revealed multiple distichiae of both upper and lower lids. Corneal findings in the right eye included a marked dorsal and paracentral corneal edema associated with a paracentral area of raised vascularized epithelium. Corneal focal fibrosis and mild neovascularization were detected dorsolaterally in the left eye. Fluorescein staining was negative OU, and intraocular pressure measured by tonometry (Tono-Pen Vet Applanation Tonometer, Reichert, Depew, NY) was within physiological limits. The rest of the ophthalmic examination was unremarkable. Hence, a diagnosis of bilateral distichiasis and secondary keratitis was made. Topical hyaluronic acid (an-HyPro 1.2% hyaluronate, an-vision, Hennigsdorf, Germany) four times a day was prescribed in order to protect ocular surface from cilium rubbing. Laser surgery to remove distichiae was scheduled in 10 days. Complete

blood count and biochemical panel revealed no abnormalities. The surgical procedure was conducted in our clinic, under general anesthesia. The calf was premedicated with 0.1 mg/kg of xylazine, administered intravenously. Following endotracheal intubation, anesthesia was maintained with isoflurane in oxygen. Periocular skin, eyelids, and ocular surface were aseptically prepared using a dilution of 10% betadine solution. Auriculopalpebral nerve block and upper eyelid line block were performed using a total of 5 ml of 2% lidocaine (S.A.L.F. S.p.A. Laboratorio Farmacologico, Cenate Sotto, Italy) in order to achieve a total desensitization of both eyelids.<sup>16</sup>

Surgery was performed using magnifying loupes (2.5X). Each distichia was treated independently by direct contact 810-nm diode laser with a flexible 4-mm tip (FOX, A.C.R. Laser GmbH, Nuremberg, Germany) with a power setting of 400 mW/s in a continuous-wave mode base on manufacturer's recommendations. The contact tip was inserted through a total of 27 Meibomian gland



**FIGURE 2** Contact diode laser therapy. The contact tip was inserted through Meibomian gland openings to destroy the hair bulb photothermally



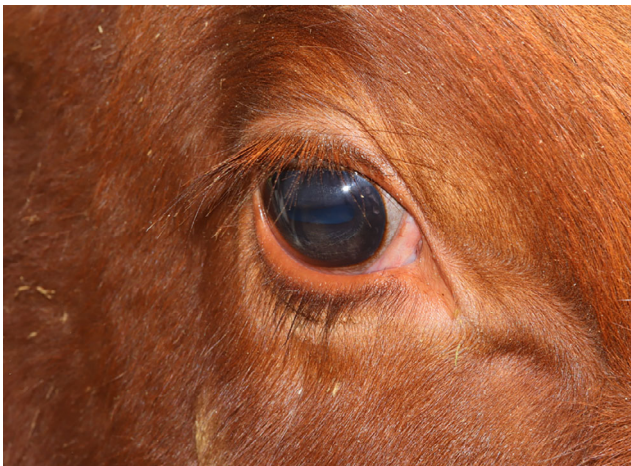**FIGURE 1** Appearance of the right and left eye at the first examination. Note the marked bilateral epiphora and the chronic corneal lesions due to irritation by multiple distichiae



openings: 7 upper right eyelid, 4 lower right eyelid, and 10 and 6 upper and lower left eyelids, respectively (Figure 2). The endpoint of treatment was reached when each distichia was easily removed using the epilation forceps. The follicle was treated again if resistance was perceived during epilation. The calf was discharged from the clinic on the day of surgery. Postoperative medical management included Meloxicam subcutaneously (0.5 mg/kg) once daily for 3 days and Ofloxacin ophthalmic ointment 0.3% (Allergan, Buckinghamshire, UK) three times daily OU until the first postsurgical re-examination.

### 3 | RESULTS

Immediate postoperative clinical appearance showed a mild blepharodema with the presence of a sero-hemorrhagic secretion derived from the openings of laserized Meibomian glands. No clinical signs of ocular pain were noted by the owner during the short-term period. Fourteen days postoperatively, the calf showed a very mild conjunctival eyelid hyperemia and a minimal



**FIGURE 3** Appearance of the right eye at 14 days after surgery. Note the absence of epiphora

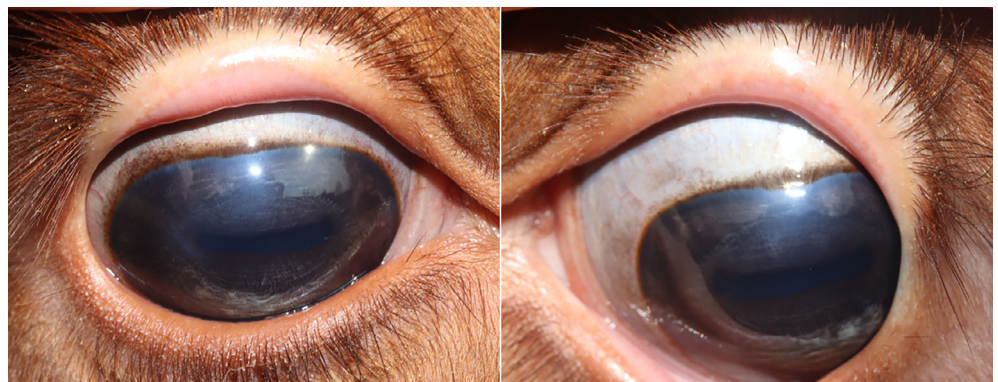eyelid swelling on the site of laser therapy. The reduction of tearing was evident (Figure 3). Ofloxacin ointment was tapered once a day for 1 week. One-month telephone follow-up revealed that the calf was still free of any signs of ocular discomfort and epiphora. Six months after procedure, the calf remained comfortable, and the eye examination revealed a bilateral slight peripheral corneal leucoma, with few ghost blood vessels (Figure 4). There was no evidence of recurrent or new distichiae.

### 4 | DISCUSSION

Distichiasis is a common clinical disorder in dogs and humans.<sup>1,14</sup> This condition has also been documented in other species, such as cat, ferret, horse, and bull.<sup>3-5</sup> The cilia emerges from the aperture of the tarsal glands and rubs against the surface of the cornea and conjunctiva. Symptomatic animals may present with ocular discomfort, and ocular examination can show signs of keratitis and conjunctivitis.<sup>1,5,7</sup> The anomalous location of the follicular root might be appeared from chronic inflammation, metaplasia of the Meibomian glands, or gene mutation.<sup>1,17</sup> Allais-Bonnet et al. investigated 78 polled cattle founding an association between being hornless and an abnormal eyelash phenotype. In most cases, additional eyelashes and hypertrichosis of the lid with an irregular orientation were found. Just in one case, a Charolais bull, distichiasis was mentioned.<sup>6</sup> To our knowledge, there are no cattle or livestock reports describing detrimental effects or treatment options of distichiasis.

Although several techniques have been developed to treat distichiasis, a definitive gold standard method has not been well-established. A successful treatment decreases patient's symptoms, minimizes recurrence, and prevents ocular surface complications.<sup>1,2,7</sup> There are few reports in veterinary ophthalmology describing rates of surgical success. Partial tarsal plate excision by performing a perpendicular section of the lid margin or by

**FIGURE 4** Appearance of the right and left eye at six months after surgery. The only abnormality noted consisted of a mild corneal haze with some dorsal ghost vessel



using a transconjunctival approach resulted in a successful outcome in 86.6% and 100%, respectively, in canine patients.<sup>8,9</sup> Results using CO<sub>2</sub> laser showed a recurrence in 2 of 11 dogs treated after a single procedure.<sup>10</sup> Regrowth of distichiae after cryotherapy treatment in dogs was not observed during a 6 months of follow-up.<sup>11</sup> Furthermore, transconjunctival thermal electrocautery technique was successful in 96% of dogs.<sup>12</sup> Postsurgical complication of these techniques such as scarring, hypopigmentation, cicatricial entropion, and qualitative tear film deficiency highlights the importance in finding an alternative effective surgical treatment to correct distichiasis in animals. Until now, no data about the use of direct-contact diode laser to treat distichiasis in veterinary medicine had been published.

Histopathological features of canine distichiasis showed that the hair roots were located in the vicinity of the Meibomian glands.<sup>17</sup> The hair starts to grow from an ectopic hair bulb; then the middle segment enters the tarsal gland and finally emerges through the excretory canal. Consequently, the laser energy is efficiently delivered to destroy the distichia bulb and the stem cells that develop new hair follicles by inserting the laser contact into the Meibomian gland.<sup>16</sup>

In humans, direct-contact diode laser has shown a success rate of 72% and 94% after a single and triple laser procedure, respectively, with an average of 1.5 treatments. In these reports the pulse wave mode with a maximal energy level of 70 J/cm<sup>2</sup>, was used whereas a continuous wave mode with a power of 400 mW was applied in the case presented here. Only two human patients required five laser treatments at 4 weeks interval.<sup>15</sup> A successful resolution of clinical signs was achieved after a single laser procedure in our case, and recurrent distichia were not detected at the last reexamination. No postsurgical complications were described after direct-contact diode laser treatment in human patients.<sup>15</sup> A transient and mild eyelid swelling on the lased sites was seen only at immediate and short-term postoperative evaluation in the case presented here; no long-term complications at 8-months follow-up due to the laser therapy were noted.

Herein, we report for the first time the successful use of the direct-contact 810-nm diode laser in the surgical management of bilateral distichiasis in a calf. Our diagnosis of presumed bilateral keratitis secondary to distichiasis was made clinically and was confirmed because of the resolution of clinical signs after a single laser treatment. Although recurrence and long-term complication were not observed, larger numbers of animals are required to assess efficacy and safety in cattle. Additionally, future histological evaluations are needed to confirm the complete atrophy of the hair bulb following

treatment using direct-contact 810-nm diode laser. Evaluation of success rate of direct-contact diode laser to treat distichiasis in animals and comparison with other surgical techniques are warranted.

## ACKNOWLEDGMENTS

The authors gratefully acknowledge Dr John S. Sapienza (Dipl. ACVO) for sharing his knowledge, expertise in support, and for critically reviewing this study.

## AUTHORS CONTRIBUTION

Kevin Arteaga (First author): contribution to the design of the study, interpretation of data, and revising intellectual content, and also final approval of the final version. Agreement to be accountable for all aspects of the work related to the accuracy or integrity of any part is appropriately investigated and resolved. Manuela Crasta (Coauthor): Revising intellectual content and final approval of the version to be published.

## CONFLICT OF INTERESTS

The authors declare no conflict of interest related to this report.

## ORCID

Kevin Arteaga  <https://orcid.org/0000-0003-0563-1744>

## REFERENCES

1. Stades F, van der Woerd A. Diseases and surgery of the canine eyelid. In: Gelatt KN, Gilger BC, Kern TJ, eds. *Veterinary Ophthalmology*. 5th ed. Oxford: Wiley-Blackwell; 2013: 840-843.
2. Bedford P. Conditions of the eyelids in the dog. *J Small Anim Pract*. 1988;29:416-428.
3. Reinstein S, Gross S, Komaromy A. Successful treatment of distichiasis in a cat using transconjunctival electrocautery. *Vet Ophthalmol*. 2011;14:130-134.
4. Verboven CA, Djajadiningrat-Laanen SC, Kitslaar WJ, et al. Distichiasis in a ferret (*Mustela putorius furo*). *Vet Ophthalmol*. 2014;17:290-293.
5. Utter ME, Wotman KL. Distichiasis causing recurrent corneal ulceration in two Friesian horses. *Equine Vet Educ*. 2012;24:556-560.
6. Allais-Bonnet A, Grohs C, Medugorac I, et al. Novel insights into the bovine polled phenotype and horn ontogenesis in bovidae. *PLoS One* 2013;8:e63512.
7. Bedford PGC. Eyelashes and adventitious cilia as causes of corneal irritation. *J Small Anim Pract*. 1971;12:11-17.
8. Gómez AP, Mazzucchelli S, Scurrrell E, et al. Evaluation of partial tarsal plate excision using a transconjunctival approach for the treatment of distichiasis in dogs. *Vet Ophthalmol*. 2020;00:1-9.
9. Bedford P. The treatment of canine distichiasis by method of partial tarsal plate excision. *J Am Anim Hosp Assoc*. 1979;15:59-60.
10. Requena IT, Ruiz NM, Marco PE. Use of CO<sub>2</sub> laser in veterinary ophthalmology. Abstracts: European Society of Veterinary

- Ophthalmologists, Prague, Czech Republic, October 14–16, 2011. *Vet Ophthalmol.* 2012;15:66-70.
11. Chambers ED, Slatter DH. Cryotherapy (N<sub>2</sub>O) of canine distichiasis and trichiasis: an experimental and clinical report. *J Small Anim Pract.* 1984;25:647-659.
  12. Zimmerman KL, Reinstein SL. Evaluation of transconjunctival thermal electrocautery for treatment of canine distichiasis: 88 eyelids (2013–2016). *Vet Ophthalmol.* 2019;22:50-60.
  13. Long RD. Treatment of distichiasis by conjunctival resection. *J Small Anim Pract.* 1991;32:146-148.
  14. Berry J. Recurrent trichiasis: treatment with laser photocoagulation. *Ophthalmic Surg.* 1979;10:36-38.
  15. RTH P, Biesman BS, Silkiss RZ. Treatment of trichiasis using an 810-nm diode laser: an efficacy study. *Ophthal Plast Reconstruct Surg.* 2006;6:445-447.
  16. Edmondson M. Local, regional, and spinal anesthesia in ruminants. *Vet Clin Food Anim.* 2016;32:535-552.
  17. Raymond-Letron I, Bourges-Abella N, Rousseau T, et al. Histopathologic features of canine distichiasis. *Vet Ophthalmol.* 2012; 15:92-97.

**How to cite this article:** Arteaga K, Crasta M. Successful treatment of distichiasis in a cow using a direct-contact 810-nm diode laser. *Veterinary Surgery.* 2021;1–5. <https://doi.org/10.1111/vsu.13617>